

## ADEQUATE SELECTION OF IMPLANTS IN AUGMENTATIVE MAMMOPLASTY

Branislav Piscevic<sup>1</sup>, Marijan Novakovic<sup>1</sup>, Dejan Vulovic<sup>2</sup>, Vladimir Stojiljkovic<sup>1</sup>

<sup>1</sup> Clinic for Plastic Surgery and Burns, Military Medical Academy, Belgrade, <sup>2</sup> Clinic for Plastic Surgery, Clinical Centar Kragujevac, Kragujevac, Serbia

## ADEKVATAN IZBOR IMPLANTATA KOD AUGMENTACIONE MAMMOPLASTIKE

Branislav Piščević<sup>1</sup>, Marijan Novaković<sup>1</sup>, Dejan Vulović<sup>2</sup>, Vladimir Stojiljković<sup>1</sup>

<sup>1</sup> Klinika za plastičnu hirurgiju i opekotine, Vojnomedicinska akademija, Beograd, <sup>2</sup> Klinika za plastičnu hirurgiju, Klinički centar Kragujevac, Kragujevac, Srbija

Received/Primljen: 07. 11. 2007. Accepted/Prihvaćen: 26. 12. 2007.

### ABSTRACT

Within the scope of the research, 56 women were subjected to augmentative mammoplasty for esthetic reasons over the period of 16 months. The follow up period lasted from 12 to 28 months. For practical reasons such as easier comparison of results, one and the same brand of implants was applied to the entire group of patients, carefully selected after detailed planning and consultations with each patient. Previous experiences were taken into consideration, as well as objective and subjective parameters, and anthropological measurements. Result of performed research has confirmed the importance of the adequate choice of implants for the development of post surgical complications.

**Key words:** mammoplasty, breast implantation, anthropometry, complications

### SAŽETAK

U okviru istraživanja koje je trajalo 16 meseci, izvršena je augmentaciona mamoplastika, iz estetskih razloga, kod 56 žena. Period praćenja iznosio je od 12 do 28 meseci. Radi lakšeg praćenja i poređenja rezultata kod svih pacijentkinja ugrađeni su implantati iste firme, pažljivo odabrani nakon detaljnog planiranja i konsultacija sa pacijentom. Korišćena su ranija poznata iskustva, objektivni i subjektivni parametri, kao i detaljna antropometrijska merenja. Rezultat obavljenog istraživanja potvrdio je značaj pravilnog izbora implantata na smanjenje nastanka različitih postoperativnih komplikacija.

**Ključne reči:** mamoplastika, implantat za dojku, antropometrija, komplikacije

### INTRODUCTION

Augmentative mammoplasty has been, and still is one of the most commonly performed procedures in esthetic surgery. Notwithstanding the existing controversies (1, 2) regarding the safety and efficiency of silicon implants, the desire of female patients to enhance their self esteem, and/or enrich their femininity, resulted in the daily increase in number of procedures performed. As a consequence, the number of complications related to this procedure (in proportion to the total number of procedures performed) has inevitably increased.

Certain number of patients have expressed discontent with performed surgical act, for either objective or subjective reasons. The breast augmentation decision making process typically starts in the first doctor/patient session. Majority of complications can successfully be avoided by careful planning and adequate decisions reached in this early stage of the process (3). Primary augmentation demands careful chest (4), as well as breast morphology (5) estimate. Surgical techniques, such as inframammary incision through the skin, under the skin and fat tissue, preparation of subglandular layer or pectoral muscle, can provide adequate bearing that reduces the risk of implant dislocation or capsular contracture. Further on, the thinned skin above the breast implant, long-term atrophy of parenchyma, or implant transparency through the skin, can be reduced or avoided by adequate selection of shape, size and type of implants, as well as adequate implant positioning. The most commonly occurring post surgical complication is capsule contracture that develops around the implant. Patients need to have clear understanding of initial and long-term risks following

the mammoplasty, as well as the possibility of occasional inavoidable repeated intervention.

### MATERIAL AND METHODS

The research was performed on a group of 56 female patients operated applying the subglandular breast augmentation technique in the Clinic for plastic surgery and burns, Military Medical Academy in Belgrade, in years 2005 and 2006. In all cases implants produced by the same manufacturer Mentor, from Santa Barbara, USA were used. Models varied from moderate to high profile, filled with silicone cohesive type II and III, volume varying between 200 and 500 ccm. In the limited number of cases, where obvious asymmetry was perceived, different size implants were used, or one side augmentation was performed.

For better planning purposes in terms of breast implants models and size, numerous additional parameters were defined, which were also monitored in the period of 5 years before the commencement of this study. The first parameter represented the quality of the breast tissue, divided in three categories: tight, medium and relaxed. The second parameter included the relation of breast versus torso, in other words, the cover of chest with breast. With respect to this, patients were divided in two groups: one with adequate cover, and the other with more modest relation. In addition, detailed measurement was performed of: the upper pole thickness of each breast, the distance between the fossa jugularis to nipple (SN-N), the distance from the middle of the clavicle to nipple (C-N), the base width of the breast (BBW), the distance of the nipple to submammary line (N-IMF), the nipple diameter as well as the space between the breasts.

Further on, the distance between sternum and nipple was also measured, space between the nipples, as well as between the nipples and the middle line. The final criteria included the size of areolas.

Inframammary surgical approach was applied in all cases, and the implant was positioned under the gland. In each case precise surgical homeostasis was applied, without using the drain or the aspiration drainage.

Hypo-allergic bandages, type hipafix, typically 6 cm wide and 25 cm long were placed to all patients immediately after the surgery. This was done in order to assure the desired implant position, as well as minimize the breast movement, especially during sleep or turning around. The strips were kept during 10 days at minimum, and up to 2 weeks. Adequate bra was used starting from the first post-surgical day. Individual physical therapy was recommended to all patients, in most cases starting from the third week after the surgery, i.e. following the removal of intradermal extended stitch (suture).

The average follow up period after the surgery lasted 12 months, 28 months at most.

**RESULTS**

During the planning and implant selection phase consultations with the patient aimed at acquiring reasonable attitude was considered to be of critical importance in order reach agreement with the patient on the most appropriate size and shape of the implant. In addition to performing surgeon’s personal experience, each patient’s psycho-physical status was taken into consideration, as well as patient’s social skills, profession, and all necessary measurements.

The research was performed on a group of 56 female patients with following preoperative dignoses: breast aplasia, hypoplasia or breast ptosis (figure 1). They have been operated applying the subglandular breast augmentation technique. In the fewer number of cases breast augmentation was performed also to female patients without any of the problems mentioned above, who have nevertheless expressed firm determination to enlarge breasts. All patients were between 18 and 53 of age (figure 2), with the body weight that varied between 46 and 110 kg. Patients’ height varied from 158 to 184 cm.

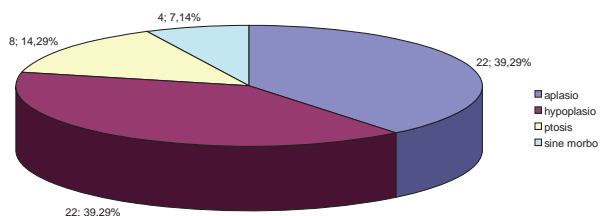


Figure 1. Preoperative diagnosis.

Fifty two patients (93%) had both-sides augmentation, and 4 were subjected to one-side augmentation (7%) (figure 3). Mentor implants, high profile type, were used with 42 patients (78%). The rest of the patients, 14 of them (22%), Mentor moderate-profile implants were built in (figure 4). Results of detailed anthropological measurements are shawn in figures 5 a-f.

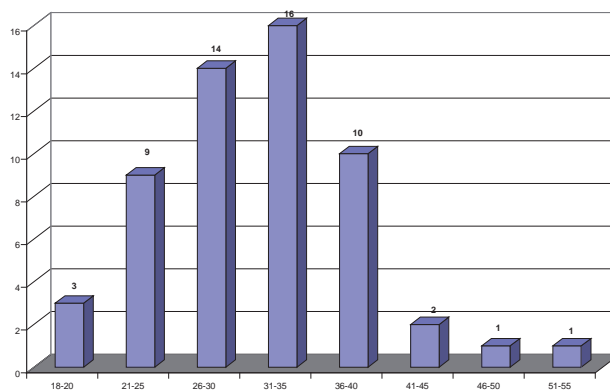


Figure 2. Age of patients.

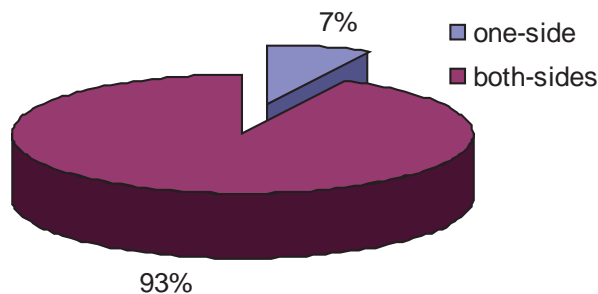


Figure 3. One-side and both-sides augmentation.

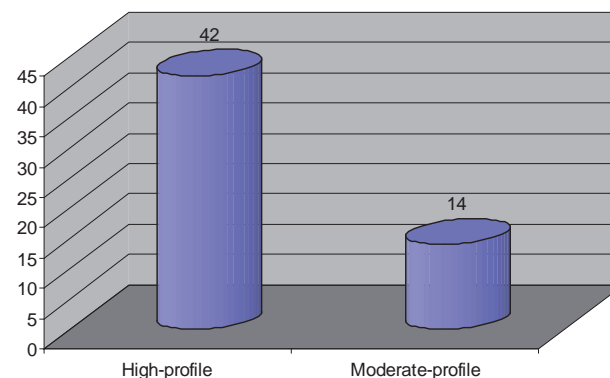


Figure 4. Implants profile.

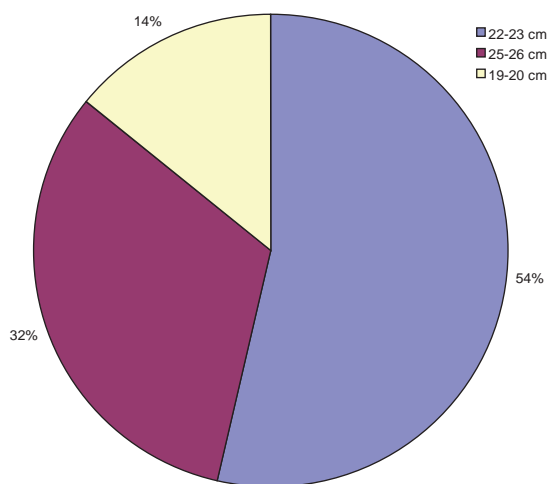


Figure 5a. Distance between the fossa jugularis to nipple (SN-N).

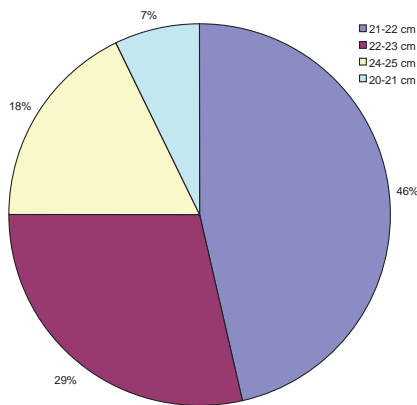


Figure 5b. Distance from the middle of the clavicle to nipple (C-N).

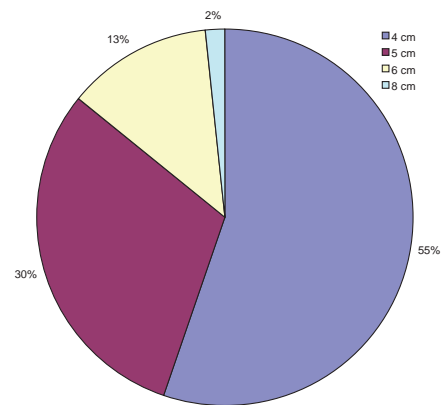


Figure 5f. Space between the breasts.

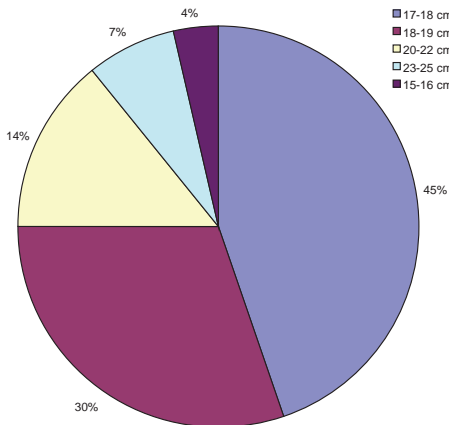


Figure 5c. Base width of breast (BBW).

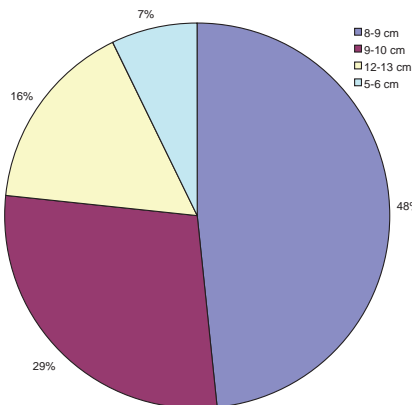


Figure 5d. Distance of the nipple to submammary line (N-IMF).

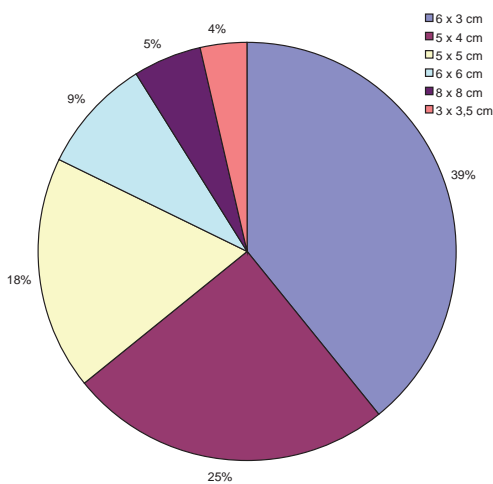


Figure 5e. Nipple diameter.

All perceived complications were divided in two groups: early and late. Of the early complications in few of the cases hematoma or seroma has occurred, on both sides in 6 cases (9.5%) (figure 6) and on one side in 3 cases (4.75%). Swelling, typically on one side, in 19 cases (33%) (figure 7), asymmetric breast sensation in 16 cases (25%), minimal asymmetry in 5 cases (11%) (figure 8), and suture dehiscence with implant prolapse in 1 case (0.45%). Late complications included one capsule contracture in one case only (0.45%) (figure 9). Distribution of complications is shown in figure 10.

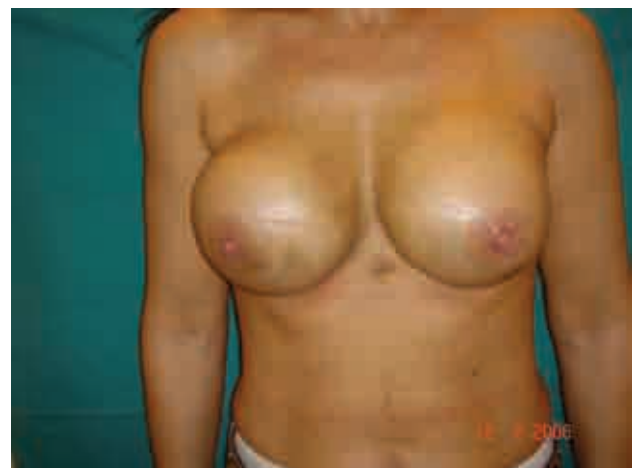

Figure 6. Hematom.

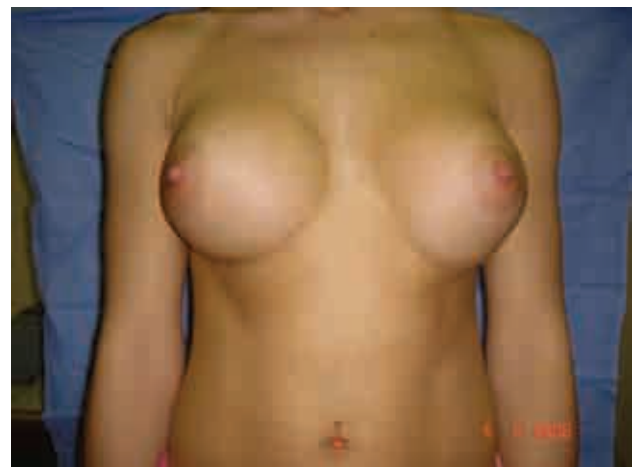

Figure 7. Unilateral swelling (right breast).

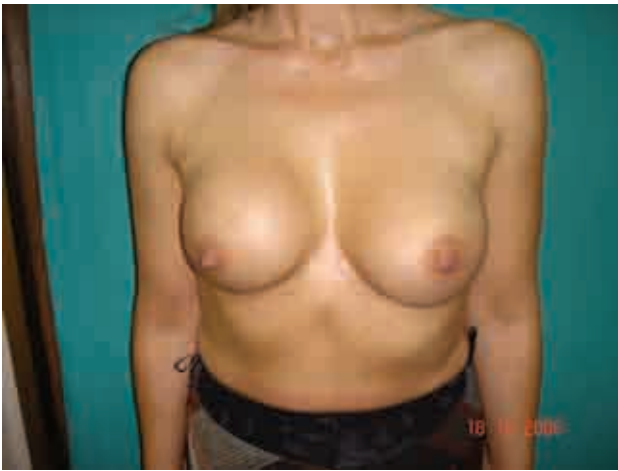

Figure 8. Assymety

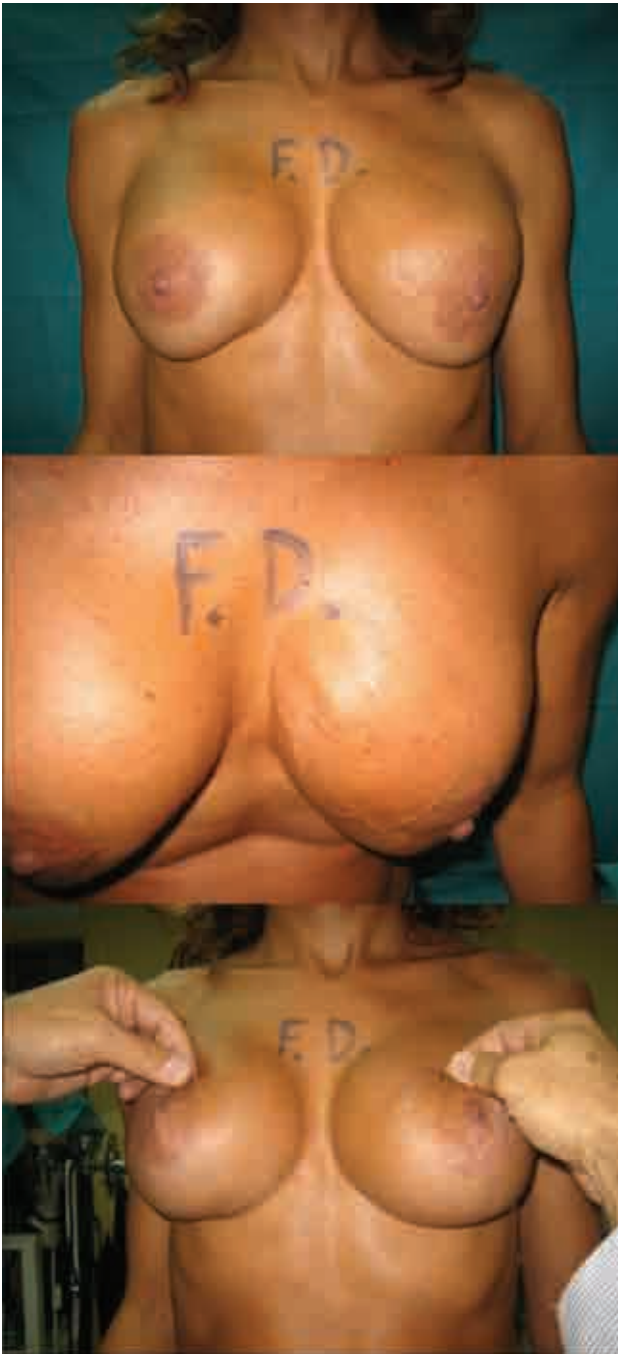

Figure 9. Capsule contracture.

One side swelling occurred in 10 cases (17%) not requiring any additional treatment. In 2 cases (1.5%) mild assymetry has occurred, of which in one case surgical correction was necessary.

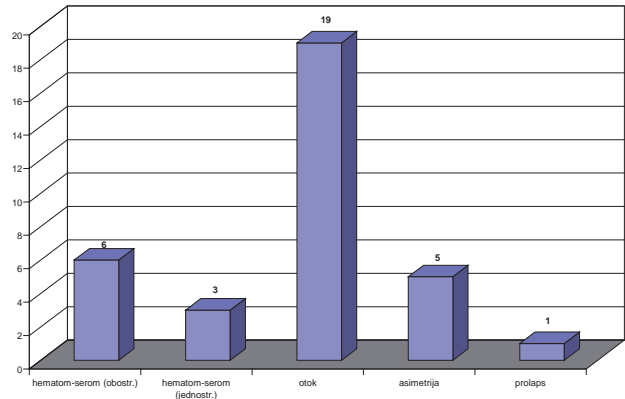


Figure 10. Complications of augmentation.

### DISCUSSION

Based on the assumption that each woman is an independent biological unity with unique anatomy, psychology and sensibility, it becomes obvious that it is not possible to repeat the previously used surgical model. Surgical experience should and has to be repeated, as well as improved, but each patient should be advised on the implant that is most compliant with her anatomy, psychological structure of personality and sensibility. And this effort should be endured.

Significant number of patients (6) report improved self confidence as the result of the operation, in the sense of increased sexuality, explaining that in certain situations they react with less inhibition, and with more sensuality.

Capsular contracture still remains the most unpredictable complication as a result of augmentative mammoplasty (7) that can increase the patient's discontent to high level. Given the modest elasticity of the chest skin, it is expected that these anatomic whole will adjust to implants of different shapes and sizes, which does not mean that significant enlargements in modest thoracic regions will not cause the tension of the skin cover at later stages, even if followed by fibrosis. In our series, the relation between life age and the degree of fibrosis has not been confirmed, which is in compliance with the findings of other authors (8). Asplund and assoc. (9) have tried to prove the causal relation between the texture of the implant itself and the development level of the contracture. However, this was proved in negligibly small percent, and therefore was not taken into consideration.

During the follow-up period (3 years after the augmentative mammoplasty), we arrived to the conclusion that the adequate selection of implants has the major effect on the overall success of the surgery. By comparing the parameters, it was concluded that in all cases with less developed thorax (10), and modestly expressed skin cover where one and the same manufacturer's implants were used, High Profile 200-350cc, no single case of



capsular contracture has occurred. In those cases where patient's decision regarding the size and shape of implants could not be effected, almost as a rule certain post-surgical complications have occurred, varying from increased pain and tension in the thoracic region with different levels of sensation, to the development of capsular contracture (in one case). In case when somewhat larger implant was placed in the less developed pectoral lodge with less exposed sub skin tissue, with which the surgeons did not fully approve, the chances for development of more severe fibrosis and even contracture have increased (11). Further on, we are of the opinion that the right decision regarding the size and the shape of the implant has long-term positive psychological impact on the patient, although there is evidence that during the first months following the surgery, when breasts have not yet achieved their final appearance, certain skepticism was perceived in terms of the size and natural looks of the breasts.

## REFERENCES

1. McGrath MH, Burkhardt BR. The safety and efficacy of breast implants for augmentation mammoplasty. *Plast Reconstr Surg* 1984; 74: 550-60.
2. Mathes SJ. Breast implantation – the quest for safety and quality. *N Engl J Med* 1997; 336: 718-9.
3. Camirand A, Doucet J, Harris J. Breast augmentation: compression--a very important factor in preventing capsular contracture. *Plast Reconstr Surg* 1999; 104: 529-38.
4. Bricout N. Chest morphology and breast augmentation. *Ann Chir Plast Esthet* 2005; 50: 441- 50.
5. Handel N, Jensen JA, Black Q, Waisman JR, Silverstein MJ. The fate of breast implants: a critical analysis of complications and outcomes. *Plast Reconstr Surg* 1995; 96: 1521-33.
6. Courtiss EH, Goldwyn RM. Breast sensation before and after plastic surgery. *Plast Reconstr Surg* 1976; 58: 1-13.
7. Gabriel SE, Woods JE, O'Fallon WM, Beard CM, Kurland LT, Melton LJ 3rd. Complications leading to surgery after breast implantation. *N Engl J Med* 1997; 336: 677-82.
8. Peters W, Smith D, Fornasier V, Lugowski S, Ibanez D. An outcome analysis of 100 women after explantation of silicone gel breast implants. *Ann Plast Surg* 1997; 39: 9-19.
9. Asplund O, Gylbert L, Jurell G, Ward C. Textured or smooth implants for submuscular breast augmentation: a controlled study. *Plast Reconstr Surg* 1996; 97: 1200-6.
10. Stokes RB. Breast augmentation in thin women: Patient satisfaction with saline-filled implants. *Aesth Plast Surg* 2004; 28:153-7.
11. Brandon HJ, Jerina KL, Wolf CJ, Young VL. Biodurability of retrieved silicone gel breast implants. *Plast Reconstr Surg* 2003; 111: 2295-306.
12. Brown MH, Shenker R, Silver SA. Cohesive silicone gel breast implants in aesthetic and reconstructive breast surgery. *Plast Reconstr Surg* 2005; 116: 768-79.
13. Okwueze MI, Spear ME, Zwyghuizen AM et al. Effect of augmentation mammoplasty on breast sensation. *Plast Reconstr Surg* 2006; 117: 73-83.
14. Pitanguy I, Vaena M, Radwanski HN, Nunes D, Vargas AE. Relative implant volume and sensibility alterations after breast augmentation. *Aesthetic Plast Surg* 2007; 31: 238-43.